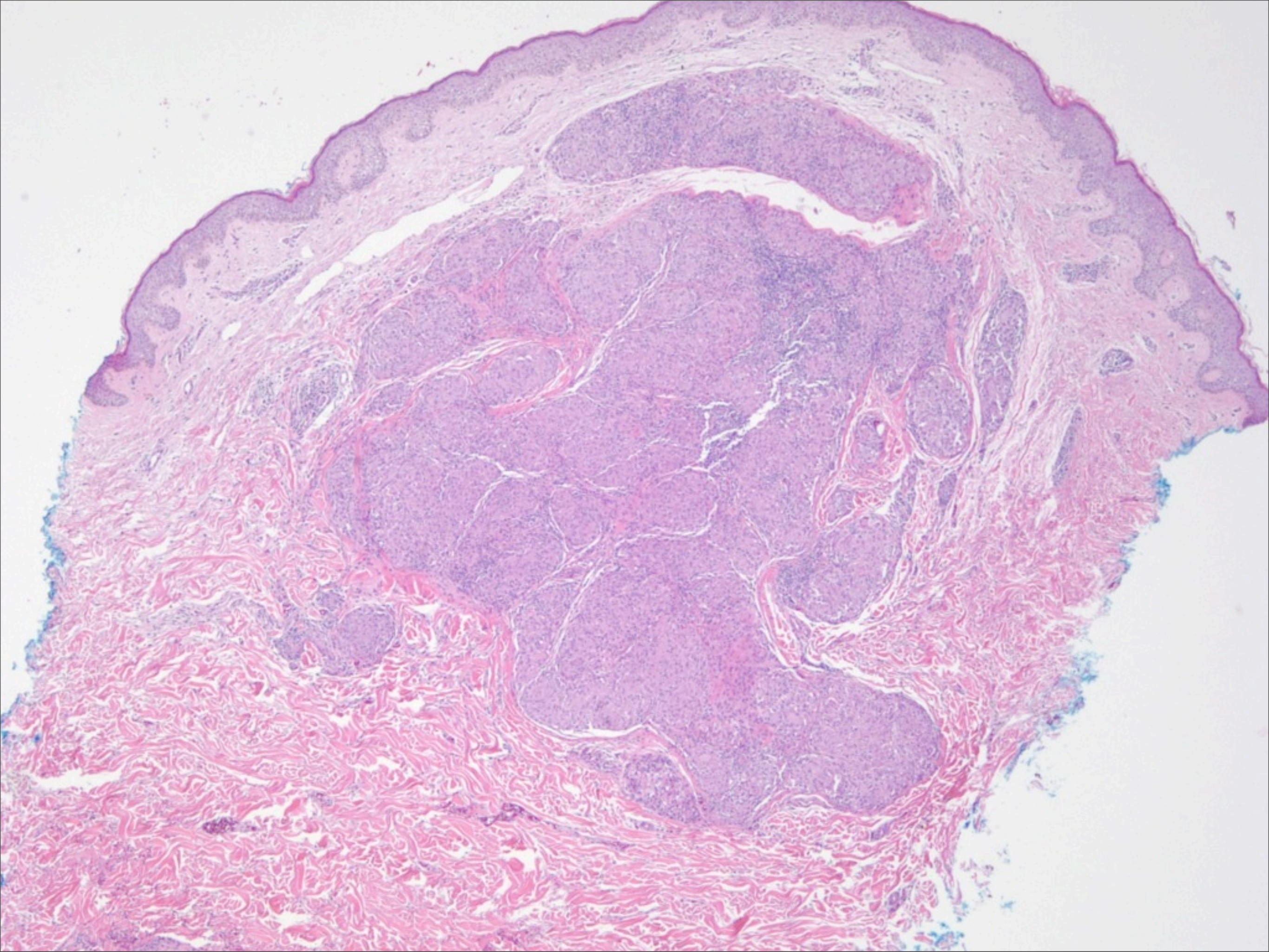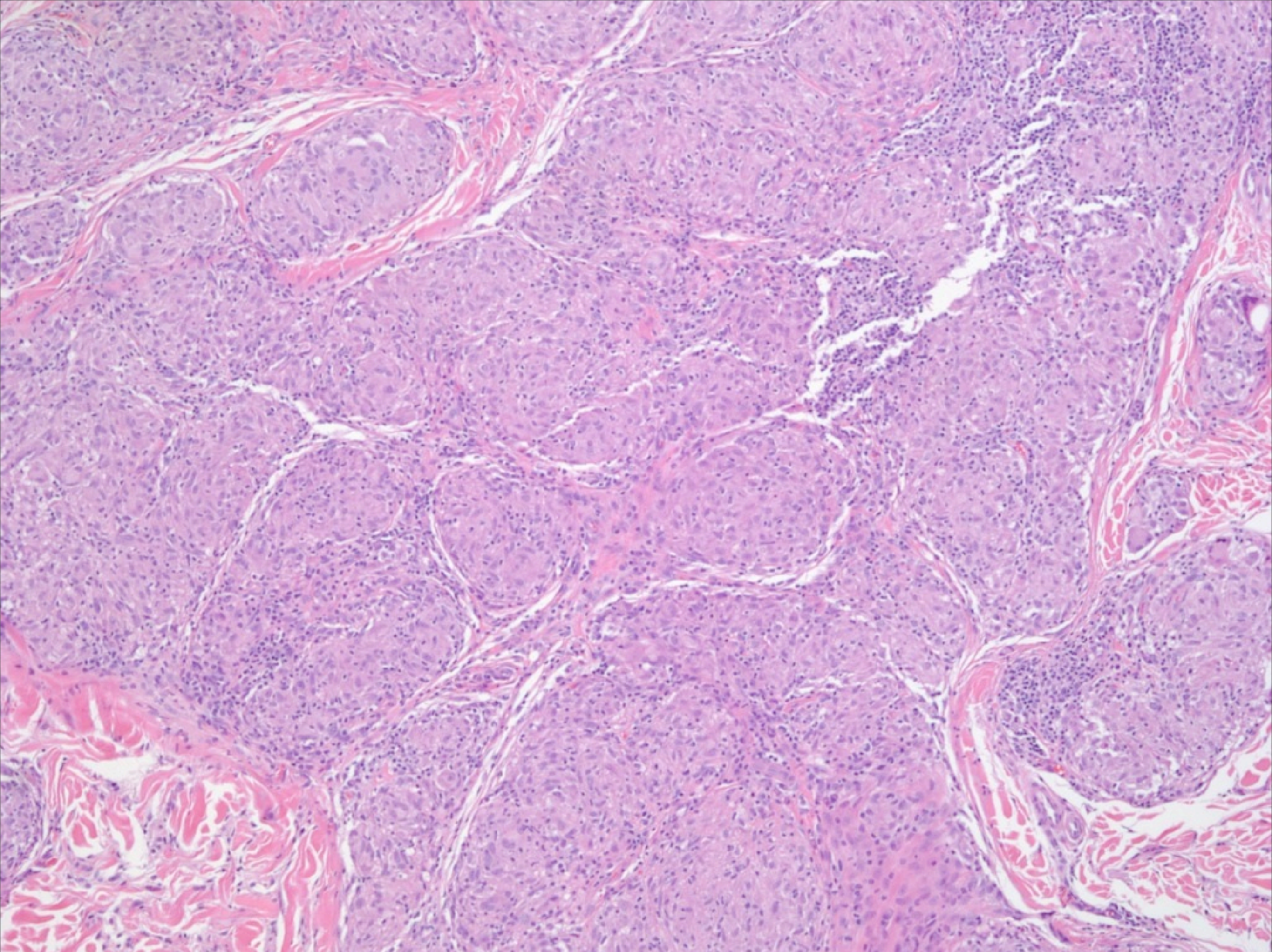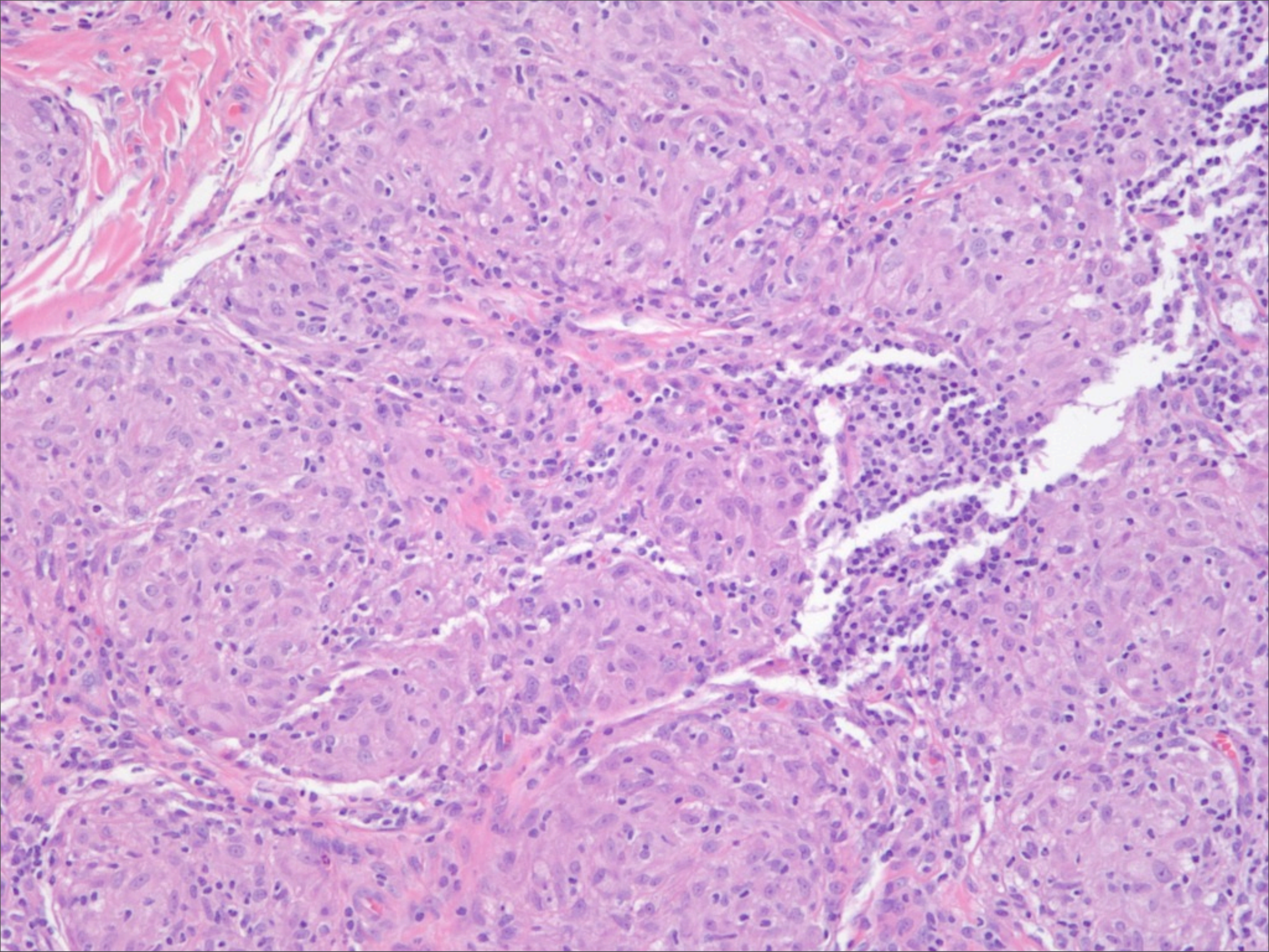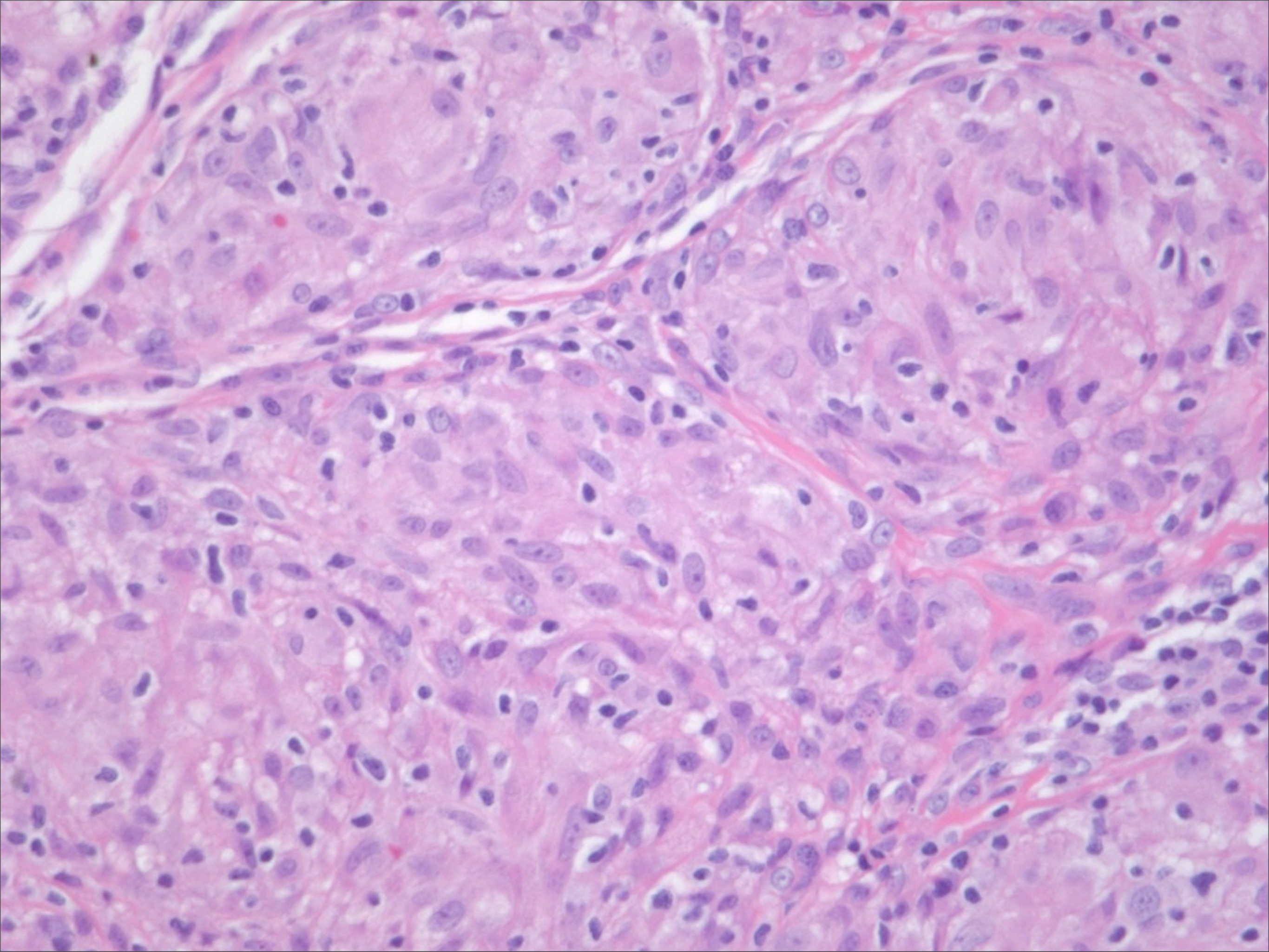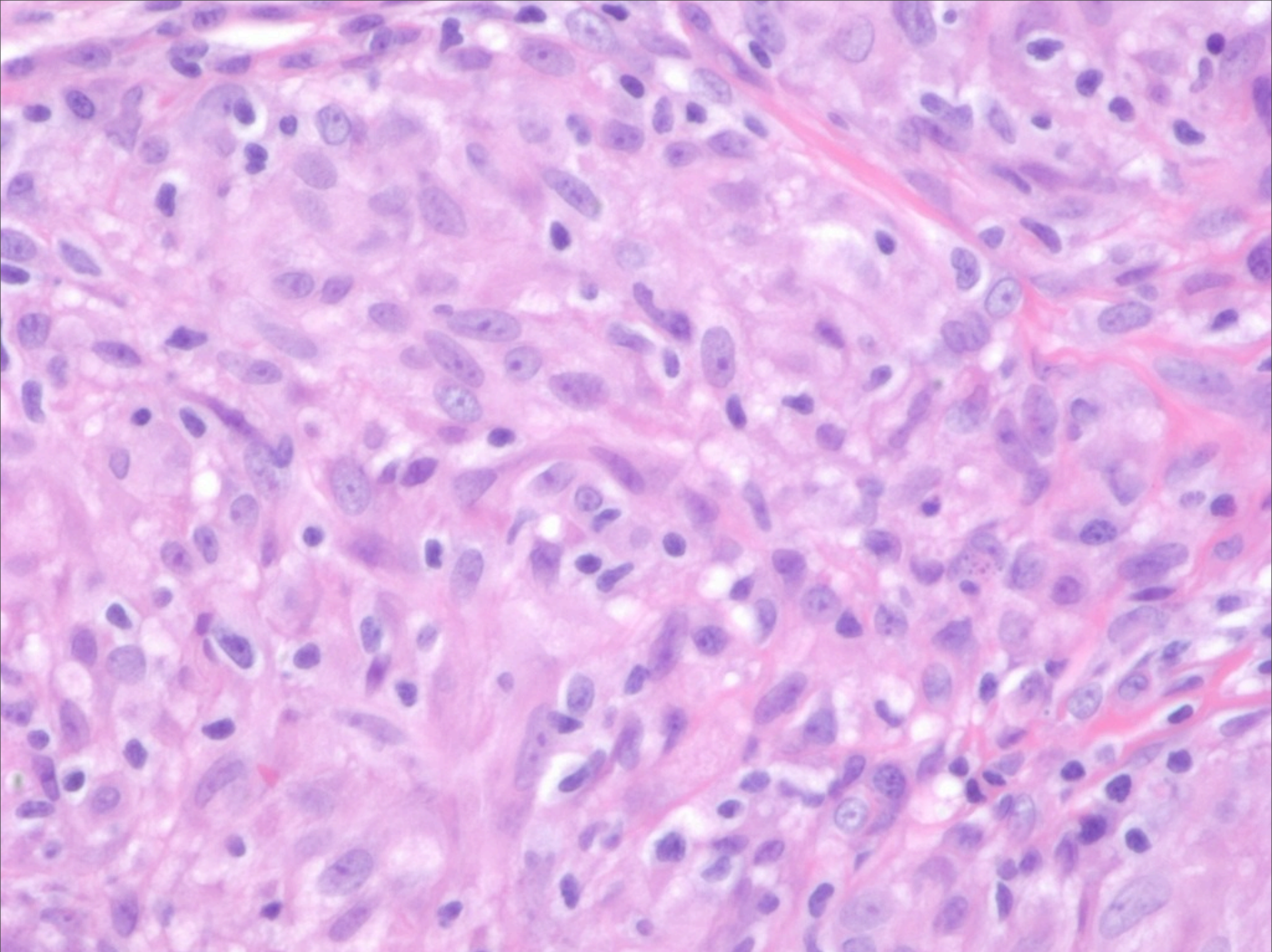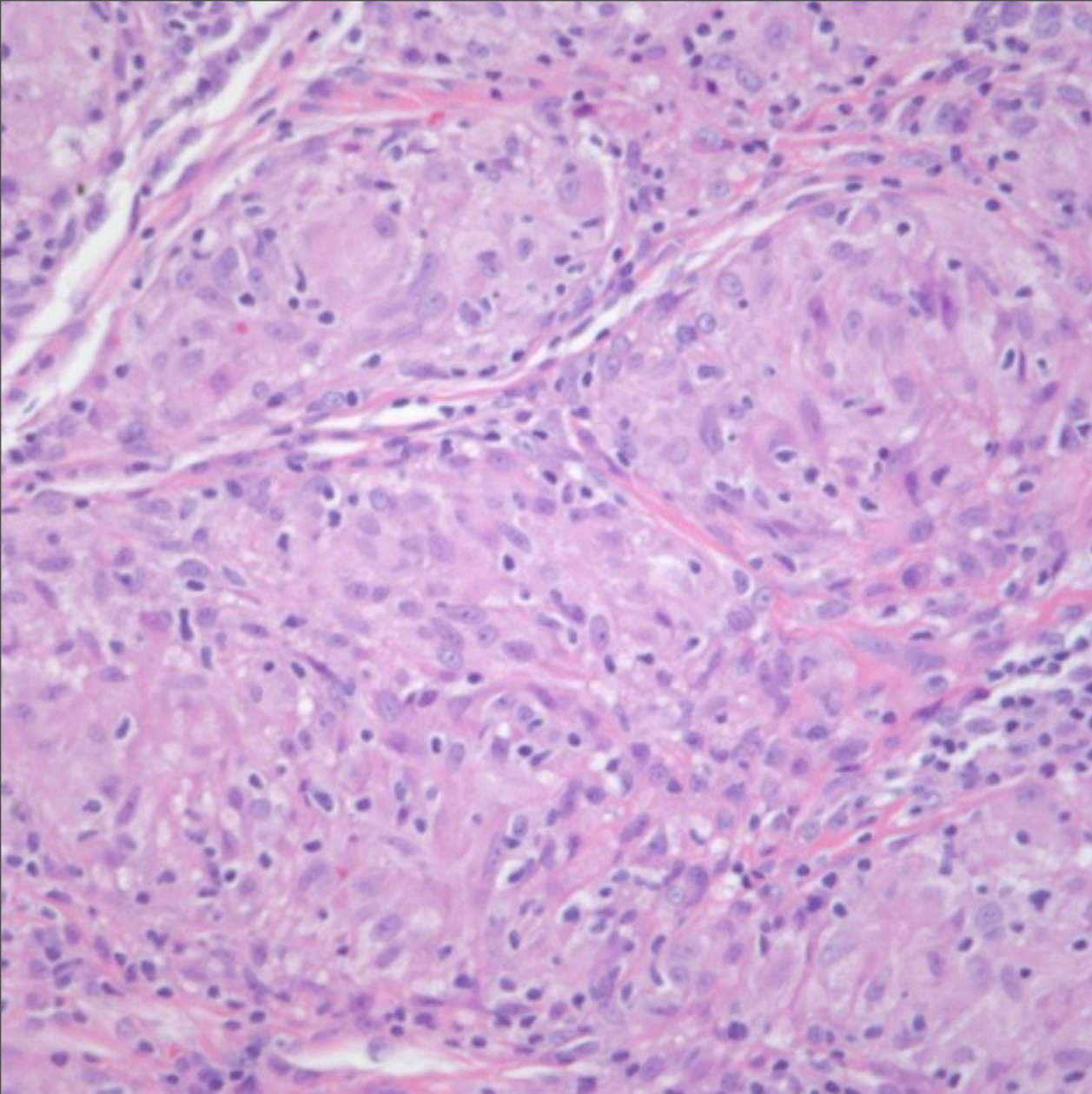


Sarcoidosis

Notes

- AFB, FITE, PAS for fungus stains were negative
- Polarization negative for retractile particles



Note: Even if polarization reveals refractile particles, does not exclude underlying sarcoidosis

Non caseating granulomas with minimal surrounding chronic inflammation “Naked granulomas”

Additional special stains to rule out infection